

In: **50th Annual Convention of the American Association of Equine Practitioners, 2004, Denver, Colorado**, (Ed.). Publisher: American Association of Equine Practitioners, Lexington KY. Internet Publisher: International Veterinary Information Service, Ithaca NY (www.ivis.org), 4-Dec-2004; P1429.1204

How to Perform Intravenous Regional Limb Perfusion Using Amikacin and DMSO

L. J. Cimetti, J. G. Merriam and S. N. D'Oench

Massachusetts Equine Clinic, Uxbridge, MA, USA.

Intravenous regional limb perfusion (RLP) is an effective adjunct therapy for the treatment of septic conditions of the equine extremity. Dimethylsulfoxide (DMSO) is a potent anti-inflammatory that acts by limiting free radical production. This paper shows that it is safe to use amikacin in a 20% DMSO solution as the perfusate for IV RLP. Note that this is an off-label use of DMSO.

1. Introduction

Septic conditions of the equine limb are a common problem and occur secondary to bacterial contamination. Bacteria may be introduced to a synovial structure or bone through a traumatic wound, surgery, or intra-articular injection. Hematogenous invasion of bacteria into a joint or tendon sheath is frequently seen in neonates but has rarely been reported in adult horses [1,2]. Infections of the extremity can be life threatening. In many cases, they cause irreversible damage and lead to permanent lameness. This report describes the use of IV regional perfusion for the adjunct therapy of acute and chronic septic conditions of the equine extremity using both amikacin and dimethylsulfoxide (DMSO) in solution. Intravenous regional limb perfusion can be performed in both the anesthetized [3] and the standing horse [4]. It has been shown that IV regional limb perfusion can achieve antibiotic concentrations in synovial fluid, bone, and soft tissue well above the minimal inhibitory concentration required to kill susceptible bacteria [5]. In chronic conditions, there is more fibrosis and scarring, which further isolate bacteria from the body's defense mechanisms as well as from systemically administered antibiotics. A high concentration of an antibiotic can be achieved in chronically infected avascular tissue by IV regional perfusion [6].

DMSO has been shown to be an effective anti-inflammatory, analgesic, and enzyme activator/inhibitor [7,8,9]. It may also possess some bacteriostatic properties as a result of its effect on the immune response and the reduction of endotoxin-induced tissue damage [7,9]. One study reported significantly decreased white blood cell (WBC) counts in the synovial fluid of joints with chemically induced synovitis treated with DMSO [10]. However, that study did not elucidate the chondroprotective effects of DMSO based on the time frame of this study. Studies have also shown increased blood flow through experimental flaps and the presence of vascular dilation with DMSO application [9]. Such properties provide rationale for its use in conjunction with an antibiotic for regional limb perfusion (RLP).

2. Materials and Methods

The medical records of 18 horses at the Massachusetts Equine Clinic between 2001 and 2003 were reviewed. These horses had septic conditions of the extremity treated with IV RLP using a 20% DMSO solution with amikacin (Table 1). In all cases, the horses were treated with IV RLP as an adjunct to systemic and local antimicrobial and anti-inflammatory therapy as well as lavage or debridement where appropriate. In cases that required general anesthesia for initial treatment, the first RLP was performed at this time. In most cases, either a single treatment or up to three consecutive treatments of the RLPs were performed, depending on the clinical progress of the horse. In many instances, the catheter was left in place and used for all three procedures.

Table 1. Case Summary of the Horses Treated With IV RLP*

Condition	No. of Cases	Age (yr)/Sex†	No. of IV RLPs	Dose of Amikacin (g)	Site of Catheter Placement† (vein)	Additional Treatments†	Long-Term Outcome†
Septic tarsocrural joint	2	10, G	3	2	m saphenous	Joint lavage	Light riding
		19, G	3	2	m saphenous	Joint lavage	Retired, light riding
Septic coffin joint	1	18, G	2	1	m/l palmar dig	Flush joint	Pasture, LTFU
Septic pastern joint (traumatic)	1	18, G	2	1	m/l palmar dig	Flush joint on day 1	Riding, FR
Septic radiocarpal joint	1	8, M	3	2	cephalic	Flush joint	Riding, FR
Osteomyelitis, P2	1	15, G	2	1	m/l palmar dig	Debride lateral P2	Riding, FR
Septic tenosynovitis	2	18, G	4	1	m/l plantar	Debride & close primarily	Light riding
		12, G	1	1	m/l plantar	Flush tendon sheath	Light riding
Septic fetlock joint	2	8, G	3	1	m/l plantar	Flush joint	Riding, FR
		6, M	1	1	m/l plantar	Flush joint	Light riding
Osteomyelitis, P3	1 (toe)	10, G	3	1	m/l palmar dig	Debride P3	Light riding
	1 (wing)	24, G	3	1	m/l palmar dig	Debride P3	Retired
Chronic pastern hyperplasia	1	9, G	1	2	m/l palmar dig	Resect and close primarily	Riding, FR
Infected mass at coronary band	1	15, M	2	2	m/l plantar dig	Resected and cast	Pasture; died from unrelated causes
Severe foot wounds (nail puncture)	4	12, G	3	1	m/l plantar dig	Flush joint	Retired, light riding
		9, G	9	1	m/l plantar dig	Flush joint; used PMMA bead packing in defect of DDFT	Trail riding/pasture
		8, G	2	1	m/l plantar dig	Debride and flush	Riding, FR
		5, M	1	1	m/l plantar dig	Debride and flush	Driving, FR

*All horses were perfused with amikacin in a 20% DMSO solution in 250 ml lactated ringers solution. All received systemic antimicrobials and anti-inflammatories.

†M, mare; G, gelding; m, medial; l, lateral; dig, digital; P2, second phalanx; P3, third phalanx; PMMA, polymethylmethacrylate; DDFT, deep digital flexor tendon; FR, full recovery; LTFU, lost to follow-up.

In all cases of standing IV RLPs, IV sedation with 0.01 mg/kg of detomidine [a] and 0.01 mg/kg of butorphanol [b] was used. Additional sedation was typically required for completion of the procedure. The area over the vessel of choice was clipped and surgically prepared. In cases involving the metacarpal/metatarsal phalangeal joint, the palmar/plantar vein was catheterized (Fig. 1). We catheterized the palmar/plantar digital vein in cases involving the distal interphalangeal joints, first phalanx (P1), second phalanx (P2), or third phalanx (P3; Fig. 2 and Fig. 3). With infections involving the tarsus, the medial saphenous vein was used, and in the case of the infected radiocarpal joint, the cephalic vein was used. Local anesthesia was applied directly over the vessel for catheter placement. A 20-gauge, 1.25-in over-the-needle catheter [c] was placed into the selected vein, an injection port [d] was applied to the end, and the port was flushed with ~1 - 2 ml of heparin [e]. The catheter was secured with tape after placement. Two Kling rolls or two rolled 4 × 4 gauze sponges were placed about mid-metacarpal/metatarsal level on either side of the third metacarpal/metatarsal over the palmar/plantar vessels, over the cephalic vein, or over the medial saphenous vein for optimal occlusion. An Esmarch bandage or rubber tubing was applied to the limb as a tourniquet and tightened over the gauze rolls. In all cases, a 20% solution using medical grade 90% DMSO [f] in 250 ml Lactated Ringer's Solution (LRS) [g] with 1-2 g of amikacin [h] added was used as the perfusate. This solution was administered through a 72-in vented primary IV set [i] pressurized with a pressure bulb, taking 3 - 5 minutes to complete. The tourniquet was left in place for 30 min after complete administration of the solution. After the perfusion, the catheter was flushed with heparin [e], and the limb was bandaged. In most cases, one catheter was used for 3 consecutive days and removed after the third treatment. In cases where there was significantly thickened, cellulitic skin, a 20-gauge needle [j] was used in place of a catheter, and the needle was removed after the procedure (Fig. 2).

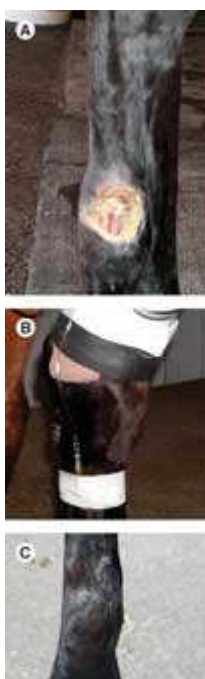

Figure 1. (A) Lacerated tendon sheath presented 2.5 mo after initial injury. (B) Intravenous RLP performed in the medial plantar vein of horse in A. (C) Lacerated tendon sheath 6 mo after surgery and treatment with IV RLP. - To view this image in full size go to the IVIS website at www.ivis.org . -




Figure 2. (A) Removal of a chronically infected proliferative mass on the palmar pastern. A 20-gauge needle was used to penetrate the skin for IV RLP. (B) The horse in A 6 wk after surgery. - To view this image in full size go to the IVIS website at www.ivis.org . -



Figure 3. (A) Horse with osteomyelitis of P3 secondary to laminitis and chronic abscessation after curettage. (B) The horse in A undergoing IV RLP. The catheter is in the lateral palmar digital vein. - To view this image in full size go to the IVIS website at www.ivis.org . -

3. Results

The overall survival rate of the horses treated with IV RLP was 89% (16 of 18). As seen in previous studies [4,11,12], no adverse reactions or complications related to RLP were observed in any of these horses. One mare died of unrelated causes after discharge from the clinic. Another horse experienced persistent lameness and was lost to follow-up.

Escherichia coli, *Staphylococcus*, and *Streptococcus* species were the most common isolates of the four cases with a positive culture. Eleven of these cases had been treated with antibiotics before referral, and no organisms could be isolated from synovial fluid samples or culture swabs taken at the time of admission.

Of the 16 surviving horses, 7 recovered fully, 6 returned to a working level desired by the owner (although a lower level than before the injury), and 2 were retired. These results support our hypothesis that it is safe to use a 20% DMSO [f]

solution with amikacin as the perfusate for IV RLP.

4. Discussion

The survival rate of the horses in this retrospective study was higher than that reported in previous studies using RLP as an adjunctive treatment of septic conditions of the equine extremity [4,12]. Septic conditions of the limb, whether traumatic or iatrogenic in origin, result in a severe inflammatory response; this leads to the accumulation of toxic metabolites, namely oxygen-derived free radicals and prostaglandins [8]. The effects of these toxic compounds are degradation of articular cartilage, development of arthritis in joints, production of fibrin, and development of adhesions in tendon sheaths. DMSO has multiple properties that can be beneficial when used in the adjunct treatment of septic conditions. DMSO acts as an anti-inflammatory by suppressing prostaglandin production [10] and scavenging free radicals through superoxide dismutase activity [10,13]. DMSO reduces platelet aggregation, and thus, decreases the incidence of thrombus formation at anastomotic sites in small vessels [7]. This activity helps to normalize tissue perfusion in the face of the vascular insults [7] that often accompany septic conditions of the equine extremity. DMSO also seems to possess both local and central nervous system analgesic activity [8,9]; the former is considered for the purpose of IV regional perfusion. The inhibitory effect of DMSO on the growth of a variety of bacteria, viruses, and fungi has been documented by a number of researchers [7,9]. It is speculated that the bacteriostatic and bacteriocidal effects of DMSO may be caused by its ability to penetrate biological membranes [7,9].

A drug that possesses these qualities is likely to attenuate some of the deleterious effects of vascular injury and free radical production inherent in septic conditions of the limb by affording a potent anti-inflammatory effect and aiding in tissue perfusion. As an adjunctive treatment of septic conditions of the extremity, we have found the combination of amikacin and a 20% DMSO solution to be an extremely safe and effective perfusate for IV RLP.

Footnotes

- a. Dormosedan, Pfizer Corp, Orion Pharmaceuticals, Exton, PA 10017.
- b. Torbugesic, Fort Dodge Animal Health, Fort Dodge, IA 50501.
- c. Abbocath-T, Venisystems, Abbott Laboratories, North Chicago, IL 60064.
- d. Locking Luer Male Adapter Plug, Abbott Laboratories, North Chicago, IL 60064.
- e. Heparin, Sodium Injection, USP, Elkins-Sinn, Inc., Cherry Hill, NJ 08003.
- f. DMSO 90%, Neogen, Triple Crown, Lexington, KY 40505.
- g. Lactated Ringers Solution, USP, Abbott Laboratories, North Chicago, IL 60064.
- h. Amifuse E, Vetus Animal Health, Burns Veterinary Supply, Westbury, NY 11590.
- i. Primary IV Set, Abbott Laboratories, North Chicago, IL 60064.
- j. Monoject 20G x40 mm, Tyco Health Care Group, Mansfield, MA 02048.

References

1. Martens RJ, Auer JA, Carter GK. Equine pediatrics: septic arthritis and osteomyelitis. *J Am Vet Med Assoc* 1986; 88:582-585.
2. Schneider RK, Bramlage RM, Moore RM, et al. A retrospective study of 192 horses affected with septic arthritis/tenosynovitis. *Equine Vet J* 1992; 24:436-442.
3. Murphey ED, Santschi EM, Papich MG. Local antibiotic perfusion of the distal limb of horses. In: Proceedings of the 40th Annual American Association of Equine Practitioners Convention 1994; 141-142.
4. Palmer SE, Hogan PM. How to perform regional limb perfusion in the standing horse. In: Proceedings of the 45th Annual American Association of Equine Practitioners Convention 1999; 124-127.
5. Murphey ED, Santschi EM, Papich MG. Regional intravenous perfusion of the distal limb of horses with amikacin sulfate. *J Vet Pharmacol Ther* 1999; 22:68-71.
6. Whitehair KJ, Adams SB, Parker JE, et al. Regional limb perfusion with antibiotics in three horses. *Vet Surg* 1992; 21:286-292.
7. Brayton CF. Dimethylsulfoxide (DMSO): a review. *Cornell Vet* 1986; 76:61-90.
8. Welch RD, DeBowes RM, Liepold HW. Evaluation of the effects of intra-articular injection of dimethylsulfoxide on normal equine articular tissues. *Am J Vet Res* 1989; 50:1180-1182.
9. Alsup EM, DeBowes RM. Dimethylsulfoxide. *J Am Vet Med Assoc* 1984; 9:1011-1014.
10. Welch RD, Watkins JP, DeBowes RM, et al. Effects of intra-articular administration of dimethylsulfoxide on chemically induced synovitis in immature horses. *Am J Vet Res* 1991; 52:934-939.
11. Scheuch BC, Vanoogmoed LM, Wilson WD, et al. Comparison of intraosseous or intravenous infusion for delivery of amikacin sulfate to the tibiotarsal joint of horses. *Am J Vet Res* 2002; 63:374-380.
12. Santschi EM, Adams SB, Murphey ED. How to perform equine intravenous digital perfusion. In: Proceedings of the 44th Annual American Association of Equine Practitioners Convention 1998; 198-201.
13. McIlwraith CW. Diseases of joints, tendons, ligaments, and related structures. In: Stashak TS, ed. *Adam's lameness in horses*, 5th ed. Philadelphia: Lippincott Williams & Wilkins, 2002; 459-644.

This manuscript is reproduced in the IVIS website with the permission of the AAEP <http://www.aaep.org>
All rights reserved. This document is available on-line at www.ivis.org. Document No. P1429.1204.



American Association of Equine Practitioners

Future Conventions : Dec. 3-7, 2005 - Seattle, WA.
Dec. 2-6, 2006 - San Antonio, TX.
Dec. 1-5, 2007 - Orlando, FL.

For more information go to <http://www.aaep.org/>

Leading the way in providing veterinary information

